Ultrasound Detected Increase in Optic Disk Height to Identify Elevated Intracranial Pressure: A Preliminary Systematic Review

Ghadi Ghanem[a], Agatha Brzezinski, MD,[b] David Haase, MD,[b] Rikke Ogawa, MLIS, [c] Alan Chiem, MD, MPH [b]

[a] David Geffen School of Medicine, University of California, Los Angeles
[b] Department of Emergency Medicine David Geffen School of Medicine UCLA and Olive View UCLA Medical Center Los Angeles USA
[c] Biomedical Library of the Health Sciences, University of California, Los Angeles

David Geffen School of Medicine

David Geffen School of Medicine

1. Background

Elevated Intracranial Pressure (eICP) is an Emergent Condition that Requires Prompt Identification, Intervention, and Monitoring

Common causes of eICP:

- **Mass lesions**
- **Traumatic bleeds**
- **Hydrocephalus**
- **Metabolic / Endocrine**
- **Infections**
- **Idiopathic**

Consequences of eICP:

- **Herniation Syndromes / Death**
- **Cerebral Ischemia**
- **Hypercarbia**
- **Seizures**

Gold Standard: Invasive eICP monitoring by extra-ventricular drainage or intra-ventricular catheters. Other (often less accurate) methods include lumbar puncture and imaging such as CT or MRI

eICP is Correlated with Optic Nerve Papilledema

Cerebral meninges are continuous with the optic nerve sheath

Non-invasive eICP monitoring by ultrasonographic (US) optic nerve sheath (ONS) diameter measurement has a pooled sensitivity of 0.90, and a pooled specificity of 0.85

The buildup of fluid in the ONS pushes the optic disc into the vitreous – causing an elevated optic disc height (ODH) , and allowing for a measurement to be obtained

2. Methods

Systematic Review following PRISMA guidelines
Inclusion: All human original articles published in English before April 2021

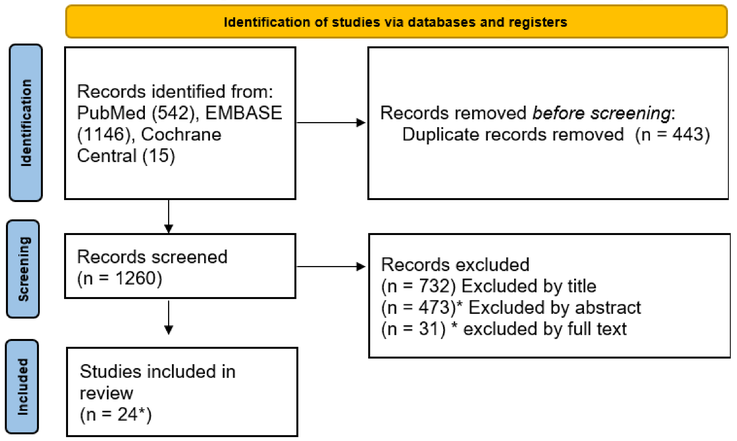

*values are preliminary and have only been screened by one reviewer and require a second reviewer.

3. Results

A total of 24 studies with a summative 891 patients were included in the review

Table 1: Studies included, condition, and number of patients

Title	Date	Author	#Participants
A Prospective Study of Optic Nerve Ultrasound for the Detection of Elevated Intracranial Pressure in Severe Traumatic Brain Injury	2020	Agrawal et al.	120 adults
Accuracy of Diagnostic Imaging Modalities for Classifying Pediatric Eyes as Papilledema Versus Pseudopapilledema	2017	Chang et al.	19 children
Detection of Optic Disc Drusen in Children Using Ultrasound through the Lens and Avoiding the Lens-Point of Care Ultrasound Technique of Evaluation Revisited	2019	Rajagopal et al.	31 children
Diagnostic Value of Systematic Imaging Examination in Embedded Optic Disc Drusen in Adolescents with Mild Visual Impairment	2020	Jia et al.	11 (13-23 yo)
Emergency point-of-care ultrasound detection of papilledema in the pediatric emergency department	2015	Ben-Yakov et al.	4 children
Feasibility and usefulness of ultrasonography in idiopathic intracranial hypertension or secondary intracranial hypertension	2016	Lochner et al. 2016	42 adults
Four-dimensional ultrasound imaging in neuro-ophthalmology	2012	Titianova et al.	30 adults
Identification of optic disc elevation and the crescent sign using point-of-care ocular ultrasound in children	2015	Marchese et al. 2015	4 children
Identification of Optic Nerve Swelling Using Point-of-Care Ocular Ultrasound in Children	2018	Marchese et al. 2018	76 children
Low energy diet and intracranial pressure in women with idiopathic intracranial hypertension: prospective cohort study	2010	Sinclair et al.	25 adult women
Neural and dural optic nerve measurements with A-scan ultrasonography	1978	Skalka et al.	115 unspecified
Ocular ultrasonography for diagnosing increased intracranial pressure in patients with severe preeclampsia	2018	Simenc et al.	60 adult women
Ocular ultrasound for monitoring pseudotumor cerebri syndrome	2018	Lochner et al. 2018	22 adults
Optic nerve sheath enlargement in acute intracranial hypertension	1994	Hansen et al.	36 adults
Point-of-care ocular ultrasound to detect optic disc swelling	2013	Teismann et al.	14 adults
Point-of-care ultrasonography for the identification of 2 children with optic disc drusen mimicking papilledema	2014	Braun et al.	2 children
Role of Orbital Ultrasound in the Assessment of Clinically Detected Papilledema	2019	Mohson et al.	80 adults
Sonographic assessment of optic nerve and ophthalmic vessels in patients with idiopathic intracranial hypertension	2018	Ba¨uerle et al. 2018	54 adults
Sonographic assessment of the optic nerve and the central retinal artery in idiopathic intracranial hypertension	2020	Jeub et al.	39 adults
Sonographic assessment of the optic nerve sheath in idiopathic intracranial hypertension	2011	Bäuerle et al. 2011	35 adults
The efficacy of optic nerve ultrasonography for differentiating papilloedema from pseudopapilloedema in eyes with swollen optic discs	2013	Neudorfer et al.	44 mixed ages
Ultrasonographic evaluation of optic disc swelling: comparison with CSLO in idiopathic intracranial hypertension	2000	Tamburrelli et al.	36 adults
Ultrasound assessment of optic disc edema in patients with headache	2012	Daulaire et al.	3 adults
Utility of Point-of-Care Ultrasound in the Diagnosis of Idiopathic Intracranial Hypertension in the Emergency Department	2021	Huo et al.	5 adults

Mean Optic Nerve Height in Papilledema

Table 2: Reported optic disc heights in patients with papilledema

Author	Reported Mean Optic Disk Height
Lochner et al. 2016	0.8 ± 0.43 mm on the right side 0.8 ± 0.38 mm on the left side
Sinclair et al.	1.02 mm (SD= 0.3 mm)
Lochner et al. 2018	0.95 mm (0.70–1.43) on the right side 1.00 mm (0.58–1.3) on the left side
Bäuerle et al. 2018	1.1 mm (SD = 0.3)
Jeub et al.	0.9 ± 0.1 mm on the right side 0.9 ± 0.1 mm on the left side
Bäuerle et al. 2011	1.1 ± 0.2 mm on the right side 1.1 ± 0.4 mm on the left side
Tamburrelli et al.	1.17 ± 0.38 mm

Reported sensitivity and specificity of US detected Papilledema varied, but showed promising results

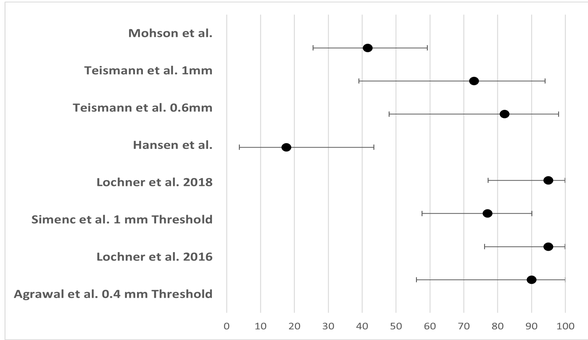

Figure 1: Reported and calculated sensitivity of studies exploring papilledema

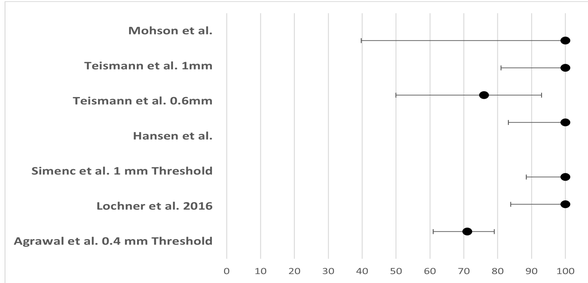

Figure 2: Reported and calculated specificity of studies exploring papilledema

4. Conclusions & Future Directions

- **ONH has the potential to be used in conjunction with ONS diameter to increase the detection rates of eICP**
- **ONH and ultrasonographic characteristics of the optic disc can aid in differentiating papilledema and pseudopapilledema**
- **Other ultrasonographic signs, such as the crescent sign and the 30-degree test may also aid in the detection of eICP, however, literature on the subjects are limited.**